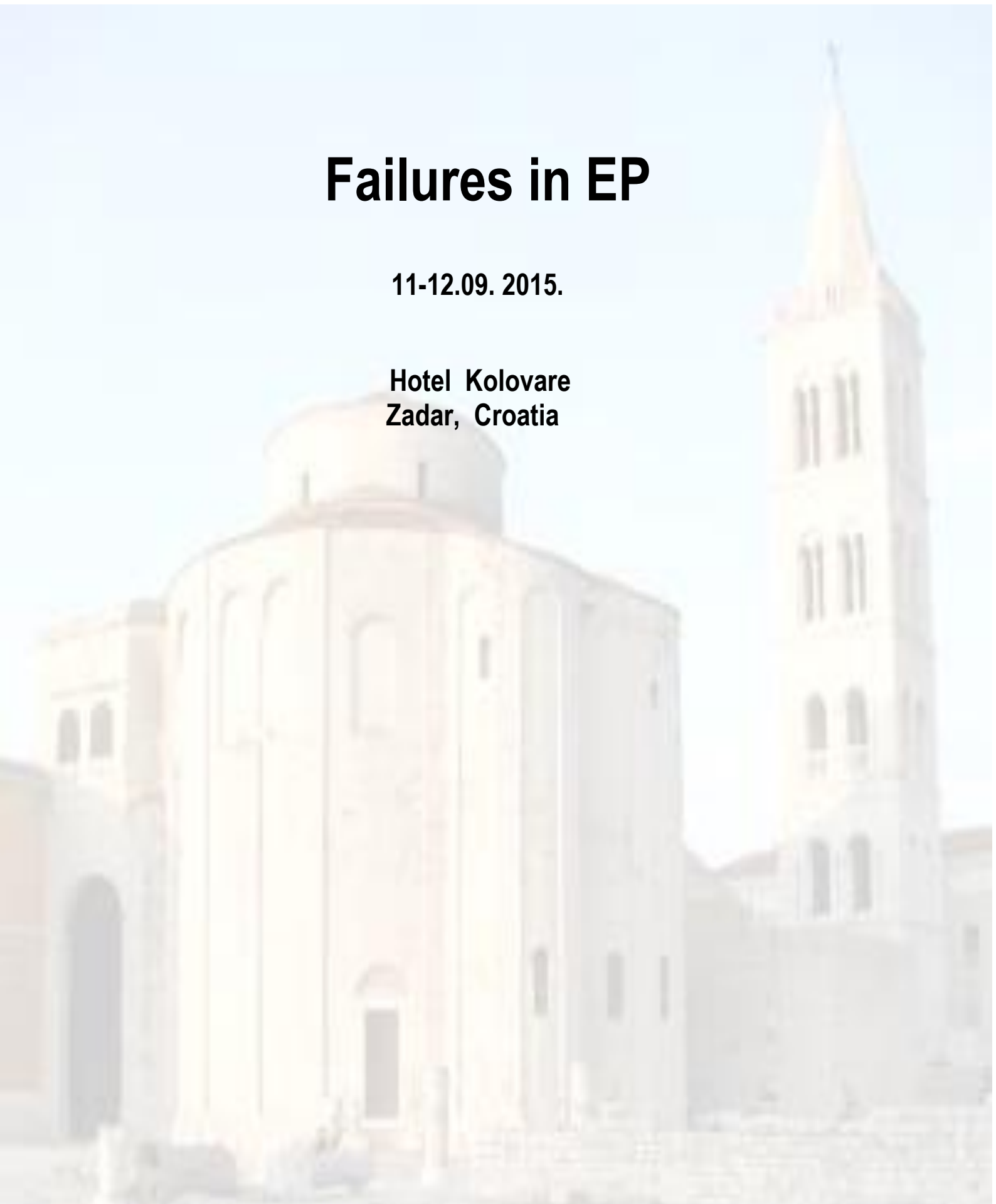


Failures in EP

11-12.09. 2015.

Hotel Kolovare
Zadar, Croatia



Failures in EP symposium

Zadar, 11-12 September 2015

Friday, September 11th, 18:00

Session 1: Failures in WPW ablation

A word from a teacher: Dr. Matjaz Sinkovec, Ljubljana, Slovenia

Case 1 - Matevž Jan (Cardiac Surgery Department, University Clinical Center, Ljubljana, Slovenia) – Cryoablation for parahisian accessory pathway – two examples

Case 2 - Cristina Tutuianu (2nd department of medicine and cardiology center, Szent Györgyi Health Center, Szeged, Hungary) – Redo ablation for the AVRT

Case 3 – Nikola Pavlović (Cardiology department, University Clinical Center Sisters of Mercy, Zagreb, Croatia) – Difficult AV(N)RT ablation

Case 4 - Marin Bištirlić (Cardiology department, General Hospital Zadar, Croatia) – Can left lateral accessory pathway ablation be challenging?

Review of lessons learned: Dr. Matjaz Sinkovec, Ljubljana, Slovenia

Session 2 : Failures in AVNRT ablation

A word from a teacher: AVNRT, the easiest arrhythmia to ablate. Tips and tricks - dr. Damijan Vokač, Maribor, Slovenia

Case 1 - Borka Pezo Nikolić (Heart and Vascular Center, University Clinical Center, Zagreb, Croatia) - Cryoablation for typical AVNRT

Case 2 - Andrej Pernat (Cardiology department, University Clinical Center, Ljubljana, Slovenia) – SVT- atypical AVNRT or parahisian focal AT?

Case 3 - Cristina Tutuianu (2nd department of medicine and cardiology center, Szent Györgyi Health Center, Szeged, Hungary) – Redo ablation for the AVNRT

Case 4 - Nedog Viljemka (University Clinical Center Maribor, Slovenia) – Report on several interesting AVNRT cases

Case 5 - Zoltan Csanadi (Department of Cardiovascular Medicine, University of Debrecen, Hungary) - Redo ablation for AVNRT. Can it be difficult?

Review of lessons learned : dr. Damijan Vokač, Maribor, Slovenia

Saturday, September 12th, 09:00

Session 1 : Failures in idiopathic ventricular arrhythmias ablation

A word from a teacher: dr. Laszlo Geller, Budapest, Hungary

Case 1- Dejan Kojić (Dedinje Institute for Cardiovascular diseases, Belgrade, Serbia) - Catheter ablation of parahisian ventricular focus

Case 2- Zoran Bakotić (Cardiology department, General Hospital Zadar, Croatia) - Multiple PVC morphologies ablated at single spot. How come?

Case 3 – Genadi Kaninski (Cardiology department, Tokuda Hospital, Sofia, Bulgaria) - Redo ILVT ablation in patient with previously implanted pacemaker

Review of lessons learned: dr. Laszlo Geller, Budapest, Hungary

Session 2: Failures in AF ablation

A word from a teacher: dr. Zoltan Csanadi, Debrecen, Budapest

Case 1- Tamas Tahin (Semmelweis Heart Institute, Budapest, Hungary): Repetitive failures in left atrial ablation- a case report.

Case 2- Peter Hlivak (National Cardiovascular Institute, Bratislava, Slovakia) : Pulmonary vein isolation – never ending story.

Case 3- Tamas Tahin (Semmelweis Heart Institute, Budapest, Hungary): Use of 3D mapping system in redo PV isolation.

Review of lessons learned: dr. Zoltan Csanadi, Debrecen, Budapest